

# Multicentre study of prepectoral breast reconstruction using acellular dermal matrix

M. Chandarana<sup>1</sup>  and S. Harries<sup>2</sup>, on behalf of the National Braxton Audit Study Group<sup>†</sup>

<sup>1</sup>Department of General Surgery, Forth Valley Royal Hospital, Larbert, and <sup>2</sup>Department of Breast Surgery, Warwick Hospital, South Warwickshire NHS Foundation Trust, Warwick, UK

Correspondence to: Mr M. Chandarana, Department of General Surgery, Forth Valley Royal Hospital, Stirling Road, Larbert FK5 4WR, UK (e-mail: drmihirchandarana@gmail.com)

**Background:** Single-stage reconstruction is used widely after mastectomy. Prepectoral implant placement is a relatively new technique. This multicentre audit examined surgical outcomes following prepectoral reconstruction using acellular dermal matrix (ADM).

**Methods:** All patients who had a mastectomy with prepectoral breast reconstruction and ADM in the participating centres between January 2015 and December 2017 were included. Demographic and treatment details, and short- and long-term operative outcomes were recorded. Factors affecting complications and implant loss were analysed: age, BMI, smoking status, diabetes, vascular disease, laterality of surgery, previous ipsilateral breast surgery or radiotherapy, indication for surgery (invasive *versus in situ* carcinoma, or risk reduction), type of mastectomy, axillary clearance, breast volume, implant volume, and neoadjuvant and adjuvant chemotherapy.

**Results:** A total of 406 reconstructions were performed across 18 centres. Median follow-up was 9.65 months. Median hospital stay was 1 day. The 90-day unplanned readmission rate was 15.7 per cent, and the return-to-theatre rate 16.7 per cent. Some 15.3 per cent of patients had a major complication, with a 90-day implant loss rate of 4.9 per cent. A further six patients had delayed implant loss. In multivariable analysis, no factor was significantly associated with complications or implant loss.

**Conclusion:** Prepectoral breast reconstruction with ADM has satisfactory surgical outcomes. The duration of follow-up needs to be extended to examine outcomes in patients who received adjuvant radiotherapy.

<sup>†</sup>Members of the National Braxton Audit Study Group are listed under the heading Collaborators.

## Funding information

DECO med

Paper accepted 3 October 2019

Published online 19 December 2019 in Wiley Online Library (www.bjsopen.com). DOI: 10.1002/bjs5.50236

## Introduction

Women undergoing mastectomy for breast cancer or risk reduction should be offered an immediate breast reconstruction if deemed suitable<sup>1</sup>. The 2011 UK National Mastectomy and Breast Reconstruction Audit<sup>2</sup> showed that about 40 per cent of women diagnosed with preinvasive or invasive breast cancer undergo mastectomy. In addition, there is increasing demand from women requesting risk reduction surgery. The past decade has seen a steady rise in implant and expander-based immediate breast reconstruction, from about 30 per cent in 2007 to 54 per cent in 2013<sup>3</sup>. There has been a gradual shift from a two-stage approach to a single-stage direct-to-implant procedure, so that one-stage prosthetic reconstruction has

become the standard technique of breast reconstruction in many centres<sup>4</sup>. Subpectoral implant placement has been the conventional method, with complete coverage of the implant using pectoralis major muscle above and acellular dermal matrix (ADM) in the lower and outer aspect. Complete implant coverage provides a larger pocket for implant placement and better control of the inframammary fold. However, animation deformity and postoperative pain related to detachment of pectoralis major muscle remain concerns<sup>5–8</sup>.

Prepectoral implant placement is a relatively new technique that avoids detachment of the pectoralis major muscle. The implant is placed in the prepectoral pocket created after skin- or nipple-sparing mastectomy, and

is usually covered by a biological or synthetic mesh. The main advantages over the subpectoral technique are claimed to be avoidance of disruption of pectoralis major muscle, less postoperative pain, no animation deformity and less capsular contracture<sup>5,9–12</sup>. Some evidence<sup>11,13–15</sup> suggests comparable, or even superior, surgical, aesthetic and cost-effective outcomes for the prepectoral technique compared with subpectoral implant placement. The use of ADM for direct-to-implant prepectoral reconstructions has been described in a number of studies<sup>16–26</sup> reporting short- and long-term outcomes. Braxon<sup>®</sup> (MBP Biologics, Neustadt-Glewe, Germany; licence-holder DECO med, Marcon, Venezia, Italy) is a novel biological mesh used for prepectoral implant-based immediate breast reconstruction. It is a porcine dermis-derived ADM of 0.6 mm in thickness, available as a preshaped template to be wrapped around the implant *ex vivo*. It allows complete coverage of the implant in the prepectoral pocket created after skin- or nipple-sparing mastectomy. Two recent multicentre European studies<sup>13,18</sup> reported acceptable operative outcomes, comparable to subpectoral reconstruction.

The present study reports on surgical outcomes from a multicentre audit conducted in the UK on prepectoral direct-to-implant reconstruction using ADM, and factors affecting complication rates and implant loss.

## Methods

The audit was initiated in August 2017. All centres across the UK performing prepectoral breast reconstructions using Braxon<sup>®</sup> ADM were invited to participate. Centres were requested to submit data on all consecutive patients undergoing skin-sparing, nipple-sparing or skin-reducing mastectomy with prepectoral implant-based reconstruction using Braxon<sup>®</sup> from January 2015 to December 2017. A National Braxon Audit Study Group included all surgeons who contributed data. Association of Breast Surgery (ABS) and British Association of Plastic, Reconstructive and Aesthetic Surgeons (BAPRAS) guidelines<sup>1</sup> were followed by participating centres for patient selection for prepectoral reconstruction. All patients operated on in the given period who had a minimum follow-up of 3 months were included. Patients who had a reconstruction using subpectoral implant placement or tissue expanders were excluded. Centres that could not submit data for patients treated before March 2018 were excluded.

Data were collected on patient demographics, treatment details, tumour characteristics and postoperative outcomes for a minimum of 90 days after surgery. Implant losses occurring after 90 days were recorded. Centres used intraoperative and postoperative antibiotics according to local protocols. Operative technique of skin- or

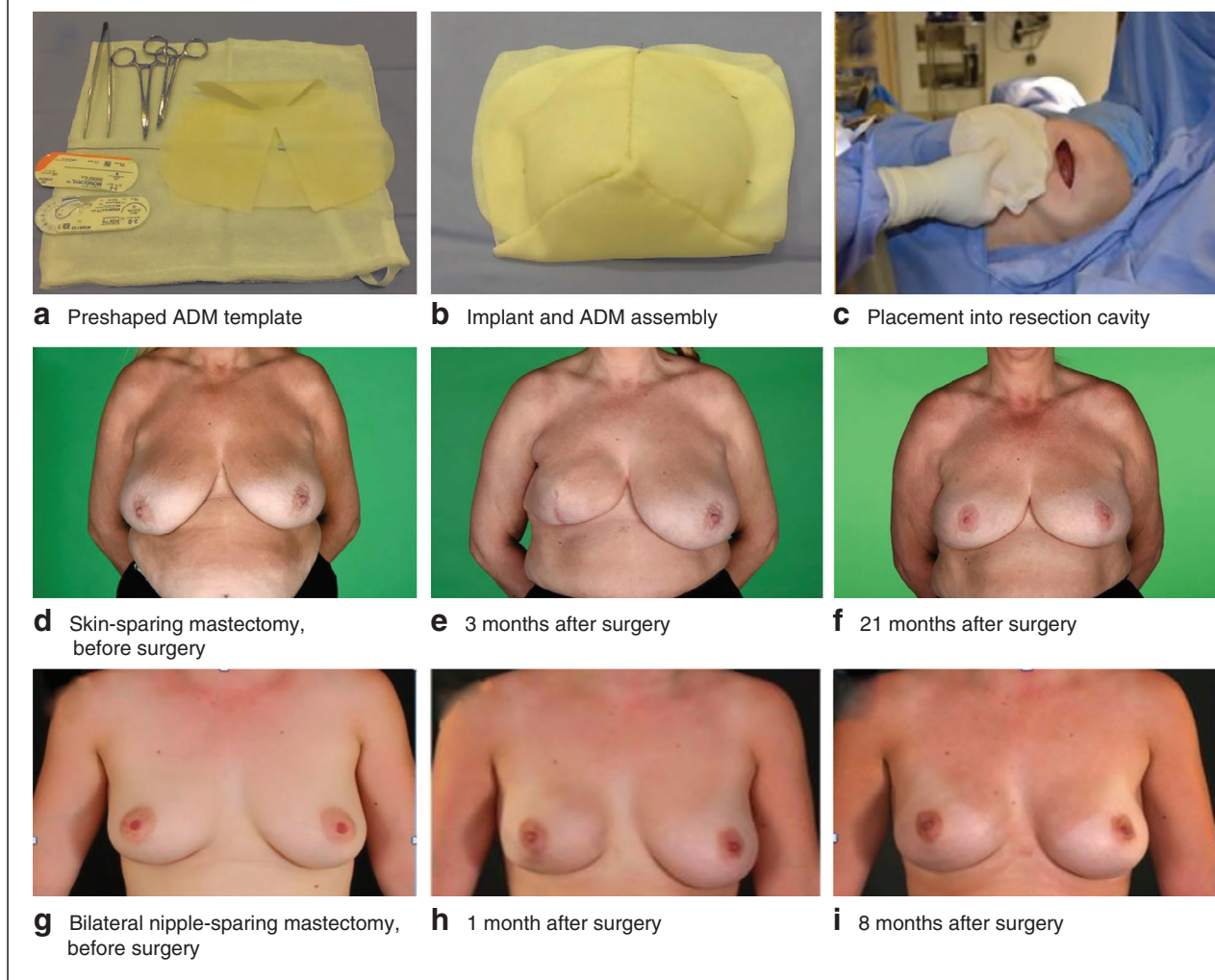
Table 1 Patient characteristics and treatment details	
	No. of patients or procedures*
<b>Total no. of patients</b>	324
<b>Total no. of procedures</b>	406
<b>Age (years)†</b>	49 (20–82)
<b>BMI (kg/m<sup>2</sup>)†</b>	25 (18–43)
<b>Laterality</b>	
Unilateral	242 (74.7)
Bilateral	82 (25.3)
<b>Smoker</b>	15 (4.6)
<b>Diabetes</b>	7 (2.2)
<b>Vascular disease</b>	6 (1.9)
<b>Previous breast surgery</b>	69 (17.0)
<b>Previous breast radiotherapy</b>	15 (3.7)
<b>Indication for surgery</b>	
Invasive disease	204 (50.2)
<i>In situ</i> carcinoma	90 (22.2)
Risk reduction/revision	105 (25.9)
Missing	7 (1.7)
<b>Type of mastectomy</b>	
Skin-sparing	224 (55.2)
Nipple-sparing	143 (35.2)
Skin-reducing	37 (9.1)
Missing	2 (0.5)
<b>Management of axilla</b>	
Sentinel node biopsy	227 (55.9)
Axillary nodal clearance	54 (13.3)
None	104 (25.6)
Missing	21 (5.2)
<b>Length of hospital stay (days)†</b>	1 (0–10)
<b>Weight of breast (g)†</b>	376 (64–3900)
<b>Implant volume (ml)†</b>	370 (105–685)
<b>Neoadjuvant chemotherapy</b>	49 (15.1)
<b>Adjuvant chemotherapy</b>	57 (17.6)
<b>Adjuvant radiotherapy</b>	62 (15.3)

\*With percentages in parentheses unless indicated otherwise; †values are median (range).

nipple-sparing mastectomy, perioperative management and drain insertion at the surgical site reflected institutional protocols or surgeon preference.

Outcomes studied were unplanned readmissions, return to theatre, postoperative complications and rate of implant loss. Specific complications recorded were seroma, skin redness or red breast syndrome, skin necrosis, infection, wound dehiscence, postoperative haematoma and capsular contracture. Redness of the wound or breast with no documented evidence of infection was classified as redness or red breast syndrome. Redness accompanied by any systemic sign of infection, positive bacteriology culture from the surgical site or blood, or a diagnosis of infection according to the treating surgeon's decision was classified as

Fig. 1 Braxon® device assembly and surgical outcomes



**a** Acellular dermal matrix (ADM) available as a preshaped template; **b** implant and ADM assembly; **c** placement of implant and ADM into the resection cavity. **d** Skin-sparing mastectomy, before surgery; **e** 3 months after surgery; **f** 21 months after surgery. **g** Bilateral nipple-sparing mastectomy, before surgery; **h** 1 month after surgery; **i** 8 months after surgery.

wound infection. Complications were categorized as major or minor based on the Clavien–Dindo grading system<sup>27</sup>. All complications of grade III or higher were categorized as major complications. Operative intervention with removal of implant was considered as implant loss. Return to theatre with exchange of implant to another implant or an expander was not considered as implant loss, but as a major complication. Implant loss or complications occurring up to 90 days after surgery were categorized as early implant loss or complications respectively. Implant loss recorded after 90 days of reconstruction was considered as delayed implant loss. Age, BMI, smoking status, diabetes, vascular disease, laterality of surgery, previous ipsilateral breast surgery or radiotherapy, indication for surgery

(invasive *versus in situ* carcinoma, or risk reduction), type of mastectomy, axillary clearance, breast volume, implant volume, and neoadjuvant and adjuvant chemotherapy were the factors studied for their impact on major complications and implant loss rates. Adjuvant radiotherapy was not considered for its impact on early complications or implant loss as it was administered after completion of adjuvant chemotherapy, more than 90 days after the primary operation.

### Statistical analysis

Data are presented as mean(s.d.) or median (range) values, or as numbers of patients or procedures with percentages

	No. of complications (n = 406)
Seroma	29 (7.1)
Skin necrosis	21 (5.2)
Red breast syndrome	16 (3.9)
Infection	13 (3.2)
Haematoma	10 (2.5)
Wound dehiscence	8 (2.0)
Pain	1 (0.2)
Capsular contracture	1 (0.2)
Other	3 (0.7)
Missing	14 (3.4)
Total	116 (28.6)

as appropriate. The  $\chi^2$  test was used for univariable analysis to calculate significance of contributing factors.  $P < 0.050$  was taken as significant. Factors found to be significant in univariable analysis were included in the multivariable model, and statistical significance was determined by logistic regression. IBM SPSS® 24.0 (IBM, Armonk, New York, USA) was used for statistical calculations and analysis.

## Results

A total of 324 women underwent 406 reconstructions across 18 centres in the UK (Table S1, supporting information). Patient characteristics and treatment details are shown in Table 1. Their median age was 49 years and median BMI was 25 kg/m<sup>2</sup>. Bilateral procedures were performed in 82 women. Half of the procedures were performed for invasive cancer, the rest for preinvasive cancer or risk reduction. Apart from two women who had a secondary reconstruction, all patients had immediate prepectoral breast reconstruction following mastectomy (Fig. 1). The median duration of hospital stay was 1 day. Median duration of follow-up for the cohort was 9.7 (range 3–35; mean 11) months; 168 women were followed for more than 12 months.

Of the 406 procedures, 116 resulted in complications, an overall complication rate of 28.6 per cent (Table 2): 62 major (15.3 per cent) and 54 minor (13.3 per cent) complications. For management of complications, 51 women (15.7 per cent of the cohort) needed an unplanned readmission and 54 (16.7 per cent) had a surgical exploration within 90 days of the primary operation. Of these, 44 women (13.6 per cent of the cohort) had a surgical exploration for implant-related complications. Some 26 implants were removed, giving an overall implant loss rate of 6.4 per cent.

	Major complications		Implant loss	
	Univariable P*	Multivariable P†	Univariable P*	Multivariable P†
Age	0.116		0.958	
BMI	0.002	0.135	0.009	0.347
Smoker	0.929		0.26	
Diabetes	1.000		0.363	
Vascular disease	1.000		0.320	
Bilateral reconstruction	0.084		0.119	
Previous breast surgery	0.351		0.594	
Previous breast radiotherapy	1.000		0.612	
Invasive breast carcinoma	0.143		0.905	
Type of mastectomy				
Skin-sparing	0.729		0.154	
Nipple-sparing				
Skin-reducing				
Axillary nodal clearance	0.002	0.063	0.072	
Breast weight	0.001	0.322	0.017	0.361
Implant volume	0.005	0.218	0.004	0.070
Neoadjuvant chemotherapy	0.778		0.749	
Adjuvant chemotherapy	0.209		1.000	

\* $\chi^2$  test; †logistic regression.



**Table 4 Comparison of present results with recommended quality criteria, National Mastectomy and Breast Reconstruction Audit and implant-based Breast Reconstruction Evaluation results**

	ABS/BAPRAS recommendation (%)	NMBRA (%)	iBRA (%)	iBRA prepectoral group (%)	National Braxon® Audit (%)
Unplanned readmission	< 5	16	18	24	15.7
Return to theatre for local complications	< 5	4.6	18	21	16.7
90-day infection rate	< 10	25	25	26	3.2
90-day implant loss rate	< 5	9	9	7	5.2

ABS, Association of Breast Surgery; BAPRAS, British Association of Plastic, Reconstructive and Aesthetic Surgeons; NMBRA, National Mastectomy and Breast Reconstruction Audit; iBRA, implant-based Breast Reconstruction evaluation.

Of these, 20 implants were removed within 90 days of the primary surgery (Table S2, supporting information), with an implant loss rate at this time of 4.9 per cent. Six women had a delayed implant loss, more than 3 months after the reconstruction. No patient with delayed implant loss had received adjuvant radiotherapy.

Of the factors studied to determine any association with early major complications or implant loss, major complications were significantly higher in univariable analysis in patients with a high BMI ( $P = 0.002$ ), greater excised breast volume ( $P = 0.001$ ), larger implant size ( $P = 0.005$ ) and axillary nodal clearance ( $P = 0.002$ ). Similarly, patients with a higher BMI ( $P = 0.009$ ), greater excised breast volume ( $P = 0.017$ ) and larger implant size ( $P = 0.004$ ) had a significantly higher implant loss. None of the factors had a significant impact on major complications or implant loss in multivariable analysis (Table 3).

## Discussion

The introduction of ADM in implant-based reconstruction has made prepectoral implant placement and complete implant coverage possible, with excellent surgical and aesthetic outcomes. This multicentre audit has demonstrated good short- and long-term surgical outcomes, with an implant loss rate of 6.4 per cent after 9 months, a 90-day major complication rate of 15.3 per cent and implant-related return-to-theatre rate of 13.6 per cent, with a resultant 90-day implant loss rate of only 4.9 per cent.

Braxon® is the only ADM currently available as a preshaped template that allows complete implant coverage *ex vivo*, facilitating direct-to-implant reconstruction of implant sizes of up to 520 ml. Other case series using this product indicated satisfactory short-term clinical and aesthetic outcomes. The implant loss rate was 12 per cent with a seroma rate of 8 per cent, using a previously manufactured thicker (0.9 mm) version<sup>16</sup>. A long-term outcome study<sup>17</sup> of ten patients, with a median follow-up of

49.2 months, reported no capsular contracture rates and minimal implant rippling in two patients. A study<sup>21</sup> that included 51 reconstructions found skin necrosis, seroma and implant loss rates of 4 per cent each. Two multicentre studies<sup>18,20</sup> have reported on short-term outcomes of prepectoral reconstruction using prepectoral implant and ADM. The first<sup>18</sup> reported on 100 reconstructions across nine centres in Europe with an implant loss rate of 2 per cent and a perioperative complication rate of 11 per cent. The other study<sup>20</sup> included 78 reconstructions reported from three centres in the UK; the implant loss rate was 10.2 per cent and the complication rate about 20 per cent. These results were comparable to national data on implant-based reconstructions in the UK<sup>2,28,29</sup>.

Information on outcomes from other ADMs and synthetic meshes for prepectoral implant-based immediate breast reconstruction is limited<sup>22,23,25,26</sup>. A recent study<sup>26</sup> included 166 reconstructions of which three-quarters had complete implant coverage using one or two sheets of ADM, whereas others had a dermal sling partially covering the implant. About one-third of the patients had a subpectoral to prepectoral conversion, about 9 per cent had an expander placement, and around 70 per cent had risk-reducing surgery, compared with approximately 25 per cent in the present audit. The overall complication rate was 11.5 per cent and implant loss rate 3 per cent.

There have been two national audits from the UK describing breast reconstruction outcomes<sup>2,28</sup>. The first audit<sup>2</sup> covered breast reconstructions performed from January 2008 to March 2009 with an implant-based reconstruction cohort of more than 3000 patients. The overall complication rate in this group was 14.7 per cent, with a return-to-theatre rate of 4.6 per cent and an implant loss rate of 9 per cent, although all were placed in a subpectoral position<sup>2</sup>. The more recent implant-based breast reconstruction evaluation (iBRA) study<sup>28</sup> included 2108 patients operated on for implant-based reconstruction between February 2014 and June 2016, but only 42 (2.0 per cent) who had a prepectoral reconstruction. Overall readmission

and return-to-theatre rates were about 18 per cent, and the 3-month implant loss rate was 9 per cent. Outcomes in the prepectoral subgroup were analysed separately and considered comparable to the overall results<sup>28</sup>. The 90-day implant loss rate in the present study was only 4.9 per cent, with an infection rate of 3.2 per cent, both of which are considerably lower than results reported in the national audits (Table 4).

Selection criteria and surgical procedures were based on ABS and BAPRAS guidelines<sup>1</sup>. In the selected cohort, 42 women had a BMI above 30 kg/m<sup>2</sup> and were counselled regarding an increased risk of complications. Patients with a higher BMI, greater excision volume and larger implant size did have significantly higher complication rates and implant loss in univariable analysis, although no factor remained significant in multivariable analysis.

This study has limitations. It is a retrospective multicentre study and will have the disadvantages of a retrospective analysis<sup>30</sup>. There is likely to have been variation in patient selection, surgical techniques and perioperative management among the participating centres. Aesthetic and patient-reported outcomes were not reported. Post-operative pain scores were available for only a minority of patients and could not be included as an outcome measure. The median duration of follow-up of 9.7 months was relatively short, and there have been reports<sup>31,32</sup> of higher complication rates and implant losses with longer follow-up intervals in patients with subpectoral reconstructions. In this series, only six implants needed removal beyond 90 days of follow-up, but much longer follow-up is necessary to identify late outcomes, particularly in women receiving adjuvant radiotherapy.

### Collaborators

The following are members of the National Braxton Audit Study Group: A. Tenovici, C. Mortimer, D. Clarke, D. Banerjee, D. Thekkinkattil, D. Predolac, D. Ferguson, E. Vaughan-Williams, G. Osborne, G. Mitchell, I. Azmy, L. Jones, N. Roche, P. Bhaskar, R. Achuthan, R. Rathinaezhil, R. Parmeshwar, S. Narayanan, S. Seetharam, S. Marla, S. Soumian, T. Sircar.

### Acknowledgements

The authors thank all members of the National Braxton Audit Study Group for contributing their data to the study.

Funding for publication of this study was provided by DECO med.

*Disclosure:* The authors declare no conflict of interest.

### References

- 1 Martin L, O'Donoghue JM, Horgan K, Thrush S, Johnson R, Gandhi A. Acellular dermal matrix (ADM) assisted breast reconstruction procedures: joint guidelines from the Association of Breast Surgery and the British Association of Plastic, Reconstructive and Aesthetic Surgeons. *Eur J Surg Oncol* 2013; **39**: 425–429.
- 2 Clinical Audit Support Unit. *National Mastectomy and Breast Reconstruction Audit 2011*. <https://files.digital.nhs.uk/publicationimport/pub02xxx/pub02731/clin-audi-supp-prog-mast-brea-reco-2011-rep1.pdf> [accessed 10 February 2019].
- 3 Mennie JC, Mohanna P-N, O'Donoghue JM, Rainsbury R, Cromwell DA. National trends in immediate and delayed post-mastectomy reconstruction procedures in England: a seven-year population-based cohort study. *Eur J Surg Oncol* 2017; **43**: 52–61.
- 4 Salgarello M, Visconti G, Barone-Adesi L. Current evidences on immediate breast reconstruction after mastectomy. *Transl Cancer Res* 2018; **7**: S339–S350.
- 5 Spear SL, Seruya M, Clemens MW, Teitelbaum S, Nahabedian MY. Acellular dermal matrix for the treatment and prevention of implant-associated breast deformities. *Plast Reconstr Surg* 2011; **127**: 1047–1058.
- 6 Hammond DC, Schmitt WP, O'Connor EA. Treatment of breast animation deformity in implant-based reconstruction with pocket change to the subcutaneous position. *Plast Reconstr Surg* 2015; **135**: 1540–1544.
- 7 Nigro LC, Blanchet NP. Animation deformity in postmastectomy implant-based reconstruction. *Plast Reconstr Surg Glob Open* 2017; **5**: e1407.
- 8 Wallace MS, Wallace AM, Lee J, Dobke MK. Pain after breast surgery: a survey of 282 women. *Pain* 1996; **66**: 195–205.
- 9 Schmitz M, Bertram M, Kneser U, Keller AK, Horch RE. Experimental total wrapping of breast implants with acellular dermal matrix: a preventive tool against capsular contracture in breast surgery? *J Plast Reconstr Aesthet Surg* 2013; **66**: 1382–1389.
- 10 Cheng A, Lakhiani C, Saint-Cyr M. Treatment of capsular contracture using complete implant coverage by acellular dermal matrix: a novel technique. *Plast Reconstr Surg* 2013; **132**: 519–529.
- 11 Baker BG, Irri R, MacCallum V, Chattopadhyay R, Murphy J, Harvey JRA. Prospective comparison of short-term outcomes of subpectoral and prepectoral strattice-based immediate breast reconstruction. *Plast Reconstr Surg* 2018; **141**: 1077–1084.
- 12 Kobraei EM, Cauley R, Gadd M, Austen WG Jr, Liao EC. Avoiding breast animation deformity with pectoralis-sparing subcutaneous direct-to-implant breast reconstruction. *Plast Reconstr Surg Glob Open* 2016; **4**: e708.
- 13 Chandarana MN, Jafferbhoy S, Marla S, Soumian S, Narayanan S. Acellular dermal matrix in implant-based immediate breast reconstructions: a comparison of

- prepectoral and subpectoral approach. *Gland Surg* 2018; **7**: S64–S69.
- 14 Cattelani L, Polotto S, Arcuri MF, Pedrazzi G, Linguadoca C, Bonati E. One-step prepectoral breast reconstruction with dermal matrix-covered implant compared to submuscular implantation: functional and cost evaluation. *Clin Breast Cancer* 2018; **18**: e703–e711.
  - 15 Casella D, Bernini M, Bencini L, Roselli J, Lacaria MT, Martellucci J *et al.* TiLoop® Bra mesh used for immediate breast reconstruction: comparison of retropectoral and subcutaneous implant placement in a prospective single-institution series. *Eur J Plast Surg* 2014; **37**: 599–604.
  - 16 Berna G, Cawthorn SJ, Papaccio G, Balestrieri N. Evaluation of a novel breast reconstruction technique using the Braxon® acellular dermal matrix: a new muscle-sparing breast reconstruction. *ANZ J Surg* 2017; **87**: 493–498.
  - 17 Berna G, Cawthorn SJ. Long term follow-up on prepectoral ADM-assisted breast reconstruction: evidences after 4 years. *Eur J Plast Surg* 2017; **40**: 255–258.
  - 18 Vidya R, Masià J, Cawthorn S, Berna G, Bozza F, Gardetto A *et al.* Evaluation of the effectiveness of the prepectoral breast reconstruction with Braxon dermal matrix: first multicenter European report on 100 cases. *Breast J* 2017; **23**: 670–676.
  - 19 Maruccia M, Di Taranto G, Onesti MG. One-stage muscle-sparing breast reconstruction in elderly patients: a new tool for retaining excellent quality of life. *Breast J* 2018; **24**: 180–183.
  - 20 Jafferbhoy S, Chandarana M, Houlihan M, Parmeshwar R, Narayanan S, Soumian S *et al.* Early multicentre experience of pre-pectoral implant based immediate breast reconstruction using Braxon®. *Gland Surg* 2017; **6**: 682–688.
  - 21 Gardani M, Simonacci F, De Sario G, Cattadori F, Rapisio E, Palli D. Prepectoral breast reconstruction using the Braxon® porcine acellular dermal matrix: a retrospective study. *Eur J Plast Surg* 2019; **42**: 145–154.
  - 22 Jones G, Yoo A, King V, Jao B, Wang H, Rammos C *et al.* Prepectoral immediate direct-to-implant breast reconstruction with anterior AlloDerm coverage. *Plast Reconstr Surg* 2017; **140**: 31S–38S.
  - 23 Sigalove S, Maxwell GP, Sigalove NM, Storm-Dickerson TL, Pope N, Rice J *et al.* Prepectoral implant-based breast reconstruction: rationale, indications and preliminary results. *Plast Reconstr Surg* 2017; **139**: 287–294.
  - 24 Reitsamer R, Peintinger F. Prepectoral implant placement and complete coverage with porcine acellular dermal matrix: a new technique for direct-to-implant breast reconstruction after nipple-sparing mastectomy. *J Plast Reconstr Aesthet Surg* 2015; **68**: 162–167.
  - 25 Paydar KZ, Wirth GA, Mowlds DS. Prepectoral breast reconstruction with fenestrated acellular dermal matrix: a novel design. *Plast Reconstr Surg Glob Open* 2018; **6**: e1712.
  - 26 Highton L, Johnson R, Kirwan C, Murphy J. Prepectoral implant-based breast reconstruction. *Plast Reconstr Surg Glob Open* 2017; **5**: e1488.
  - 27 Dindo D, Demartines N, Clavien P-A. Classification of surgical complications: a new proposal with evaluation in a cohort of 6336 patients and results of a survey. *Ann Surg* 2004; **240**: 205–213.
  - 28 Potter S, Conroy EJ, Cutress RI, Williamson PR, Whisker L, Thrush S *et al.*; iBRA Steering Group; Breast Reconstruction Research Collaborative. Short-term safety outcomes of mastectomy and immediate implant-based breast reconstruction with and without mesh (iBRA): a multicentre, prospective cohort study. *Lancet Oncol* 2019; **20**: 254–266.
  - 29 NHS Digital. *National Mastectomy and Breast Reconstruction Audit, Annual Report – 2009*. <https://digital.nhs.uk/data-and-information/publications/statistical/national-mastectomy-and-breast-reconstruction-audit-annual-report/national-mastectomy-and-breast-reconstruction-audit-annual-report-2009> [accessed 10 February 2019].
  - 30 Sedgwick P. Ecological studies: advantages and disadvantages. *BMJ* 2014; **348**: g2979.
  - 31 Barber MD, Williams L, Anderson EDC, Neades GT, Raine C, Young O *et al.* Outcome of the use of acellular-dermal matrix to assist implant-based breast reconstruction in a single centre. *Eur J Surg Oncol* 2015; **41**: 100–105.
  - 32 Bennett KG, Qi J, Kim HM, Hamill JB, Pusic AL, Wilkins EG. Comparison of 2-year complication rates among common techniques for postmastectomy breast reconstruction. *JAMA Surg* 2018; **153**: 901–908.

### Supporting information

Additional supporting information can be found online in the Supporting Information section at the end of the article.